



# Posterolateral neck dissection: preoperative considerations and intraoperative technique

Jonah D. Klein, BA,<sup>a</sup> Jeffrey Myers, MD, PhD,<sup>b</sup> Michael E. Kupferman, MD<sup>b</sup>

From the <sup>a</sup>Temple University School of Medicine, Philadelphia, PA; and

<sup>b</sup>Department of Head & Neck Surgery, MD Anderson Cancer Center, Houston, TX.

## KEYWORDS

Neck dissection;  
Melanoma;  
Skin cancer

Posterolateral neck dissection has become the standard operative technique in the surgical management of metastatic adenopathy among patients with cutaneous malignancies of the posterior neck and scalp. This technique has been used in both the staging and therapeutic settings but is reserved today primarily for oncological resection of clinical disease. This dissection includes removal of lymph node levels II through V along with the suboccipital, retroauricular, and nuchal nodes, which are common sites of spread for cutaneous malignancies of the posterior scalp, suboccipital region, retroauricular region, and posterosuperior neck. The most common indication is for metastatic cutaneous malignant melanoma and squamous cell carcinoma, although soft-tissue sarcomas can present in this region and necessitate regional dissection. The aim of this review is to delineate the preoperative evaluation and intraoperative considerations of the posterolateral neck dissection.

© 2013 Published by Elsevier Inc.

The decision to perform a posterolateral neck dissection is dictated by the location of the primary tumor and respective lymph drainage patterns. Of the 4 functional drainage patterns described and imaged by Lengele et al, the posterior scalp and retroauricular cutaneous regions of the head and neck primarily follow the posterior accessory pathway and the superficial lateral pathways.<sup>1</sup> Drainage first enters the suboccipital and retroauricular nodes, followed by likely entry into the jugulodigastric nodes of level IIB, superficial jugular nodes, and subsequently to the deep nodes of levels VA and VB.<sup>1,2</sup> This anatomic drainage provides a rationale for removal of levels II-V, retroauricular, and suboccipital nodes in the procedure that Rochlin, in 1962, termed posterolateral neck dissection (Figures 1 and 2).<sup>3</sup>

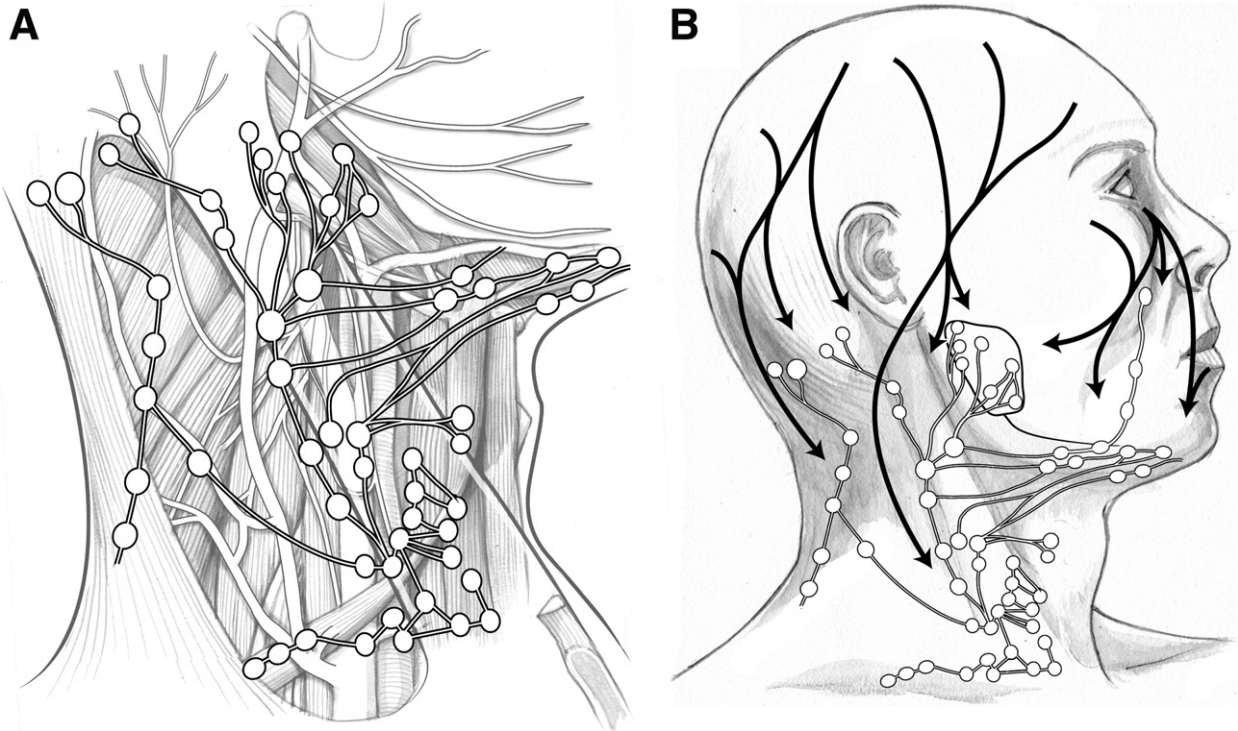
Several studies have demonstrated the anatomic details and oncological impact of the posterolateral neck dissection. In

1980, Goepfert et al at the MD Anderson Cancer Center documented 17 patients with cutaneous malignant melanoma (CMM) or squamous cell carcinoma (SCC) of the posterior scalp who underwent a posterolateral neck dissection, nearly all for gross nodal disease. There was 1 local recurrence and no recurrence in the neck of any of these patients. This approach was further substantiated in a subsequent study that included 55 patients with primarily CMM and SCC. Among patients undergoing a posterolateral neck dissection, disease at the primary site was controlled in 89% of patients, and disease in the regional nodal basin was controlled in 93% of patients. Although it is notable that most patients received adjuvant therapy, the oncological rationale for the technique was confirmed.<sup>4,5</sup> Other studies support posterolateral neck dissection to achieve locoregional control for patients with invasive CMM, SCC, or Merkel cell carcinoma in the suboccipital, retroauricular, or parieto-occipital region.<sup>6,7</sup>

These and other studies provide the best documented evidence that a posterolateral neck dissection is an efficacious procedure and is indicated for patients with malignancies of the posterior scalp, retroauricular region, and upper posterior neck, as most patients had locoregional control despite a significant incidence of nodal disease.<sup>8-10</sup>

**Address reprint requests and correspondence:** Michael E. Kupferman, MD, Department of Head & Neck Surgery, MD Anderson Cancer Center, 1515 Holcombe Boulevard, Unit 1445, Houston, Texas 77030.

E-mail address: MEKupfer@mdanderson.org.

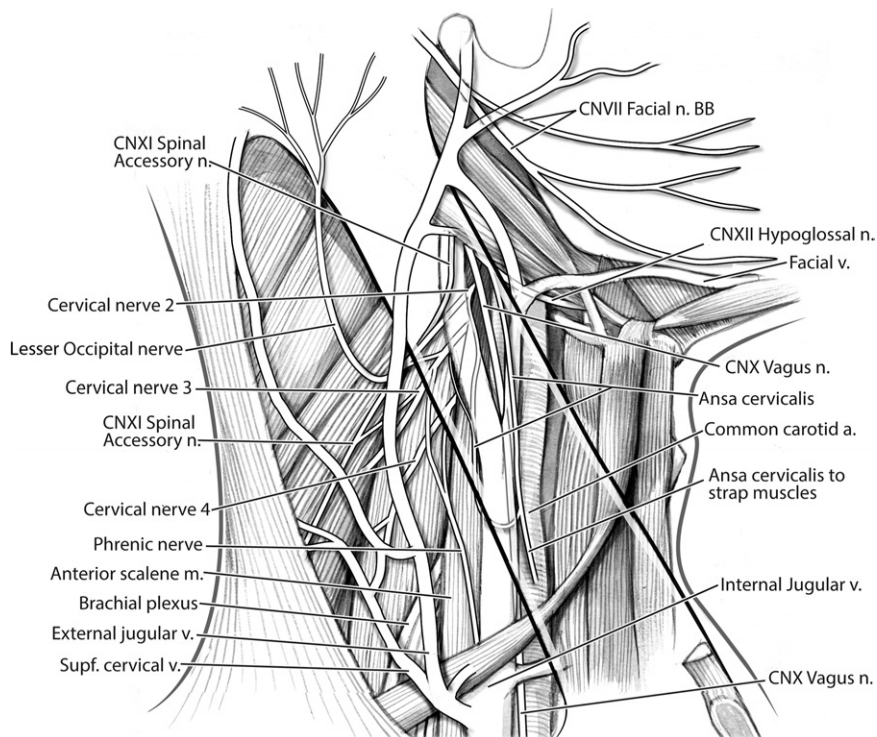


**Figure 1** Delineation of A, cervical lymph node levels and B, lymphatic drainage from distinct regions of the head and neck. Minimally modified and reprinted with permission.<sup>1</sup>

**Preoperative planning**

For any patient with nodal metastasis that warrants a PLND, a focused presurgical history and physical examination is mandated. Attention should be given to the anatomic extent of the nodal burden and involvement of regional structures,

as resection of involved skin, deep neck musculature, salivary glands, blood vessels, or nerves may be necessary. The function of the spinal accessory nerve and the brachial plexus should be assessed preoperatively. Surgical and radiation history should be elicited, as the surgical approach



**Figure 2** Schematic representation of anatomy of the head and neck encountered during a posterolateral neck dissection.

may need to be altered to accommodate previous incisions. Preoperative counseling should focus on the risks of injury to the hypoglossal, spinal accessory, facial, and phrenic nerves, as well as the brachial and cervical plexuses. In addition to the attendant risks of any surgical procedure, the risk of a chyle leak should be discussed.

All patients who are planned to undergo a PLND should undergo imaging of the head and neck. For most surgeons, an axial computerized tomography with intravenous contrast of the head and neck is useful to determine the location of the primary tumor and in determining the presence of nodal disease. If nodal disease is identified on computerized tomography, a fine needle aspiration biopsy, performed at the time of diagnostic ultrasonography, would be useful for histologic confirmation of disease in other nodal basins, information that would potentially alter the intraoperative strategy. In the setting of regional metastasis, most physicians would evaluate the patient for distant metastasis with either a positron emission tomography scan or full-body imaging. For patients with melanoma, a magnetic resonance imaging of the brain should complete the metastatic workup.

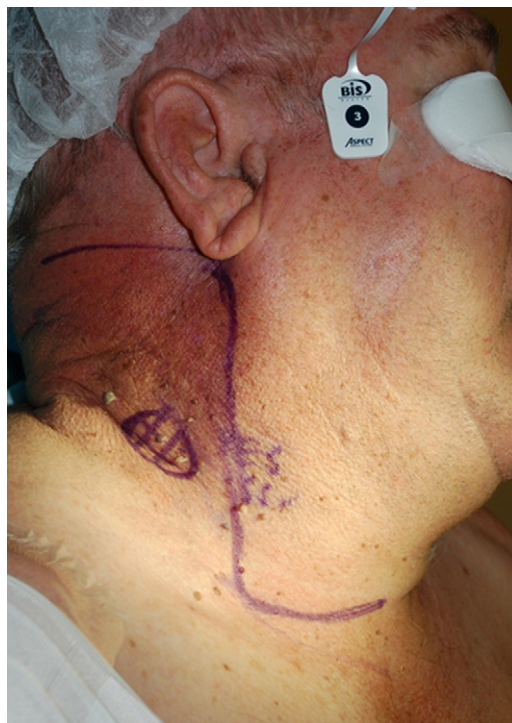## Technique

### Patient positioning

After the induction of general anesthesia, the patient is placed in the supine position, with a shoulder roll placed under the ipsilateral shoulder. Alternatively, the patient is placed in the lateral decubitus position and secured with a deflated bean bag.<sup>5</sup> Surgeon preference and extent of dissection should determine the optimal patient position. For bilateral posterolateral neck dissections, the patient is placed in the prone position.<sup>6</sup> Both upper extremities should be tucked at the patient's side, and the operative table is turned 180°.

### Preparation

Lidocaine (1%) with epinephrine (1:100,000) is injected along the proposed incision (described in the following section), as long as there are no medical contraindications. The neck, shoulder, upper chest, ear, and scalp are cleansed with povidine-iodine solution, and drapes and towels are placed to expose the posterior neck superior to the nuchal line, inferior to the clavicle, and to expose the anterior midline of the neck and ipsilateral auricle. If the primary tumor is in proximity to the field of dissection and is being included in the margins, then this area is also prepped and exposed.<sup>4,5</sup> If a large skin or soft-tissue defect is anticipated, the chest wall should be included in the sterile field to accommodate a pectoralis major myocutaneous or myofascial rotational flap.



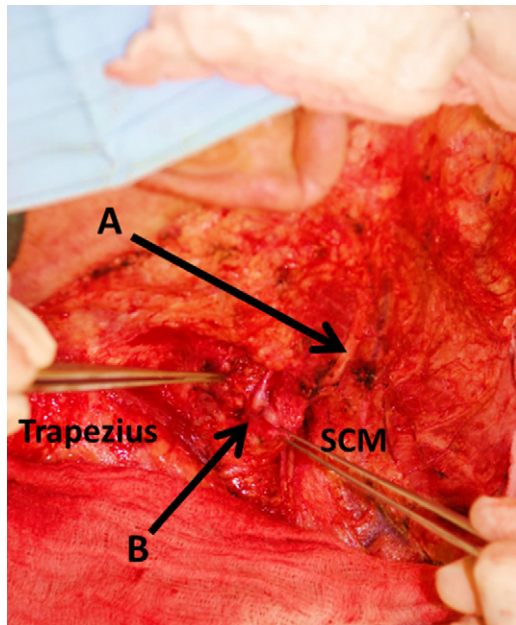
**Figure 3** The “S” shaped incision beginning anteriorly and horizontally along a cervical neck fold, followed vertically and superiorly, then ending along the nuchal line posteriorly.

### Incision

When making the incision, consideration must be given to the site of the primary tumor, its inclusion in the resection, and the location of previous incisions such as node biopsies. Barring these considerations, the following describes the course of the incision. The incision is a continuous 3-limb incision, described as a “hockey stick” incision or an “S” incision (Figure 3). The first limb begins at the midline of the anterior neck along a cervical skin fold. The second limb extends vertically and superiorly along the posterior border of the SCM, ending at the mastoid tip. The third limb extends horizontally and posteriorly along the nuchal line to the midline of the occiput. The initial incision can be made with a knife, followed by electrocautery to begin flap elevation. Alternatively, the inferior limb can be made to extend posteriorly into the level V region.

### Flap elevation

The skin flap elevation begins anteroinferiorly with the elevation of the platysma muscle medially to expose the fibrofatty tissue in the subplatysmal plane. The platysma is elevated in a broad front superiorly along the SCM to expose the greater auricular nerve and the external jugular vein (Figure 4). The subplatysmal flap is further elevated superiorly and anteriorly to expose the posterior and inferior border of the submandibular gland, which is the anterior extent of dissection. Identification of the marginal mandibular nerve is not necessary, provided that the submandibular gland is not resected; rather, the nerve is left undisturbed in



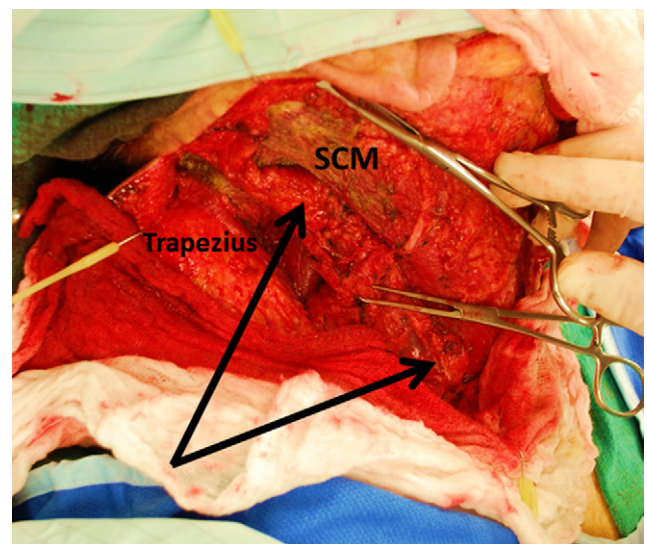
**Figure 4** (A) Identification of the greater auricular nerve on the superficial border of the SCM exposed after elevation of the subplatysmal flap. (B) The spinal accessory nerve exiting the SCM being traced to the trapezius through the fascia of level V. (Color version of figure is available online.)

the fascia overlying the gland. The subplatysmal dissection should continue posteriorly into the level V region until the trapezius muscle is identified. The posterosuperior plane of dissection, where there is no platysma muscle, corresponds to the region in which the spinal accessory nerve should be identified. Elevation of this aspect of the skin flap commences posterior to the greater auricular nerve. The posterior skin flap is elevated subcutaneously until reaching the superior-anterior aspect of the trapezius, which is the posterior extent of flap elevation. Finally, the superior flap is elevated below the auricle to expose the underlying node-bearing tissue in the suboccipital and retroauricular region. Once the borders of dissection have been reached, the flaps are secured and the skin edges kept moist with wet sponges.

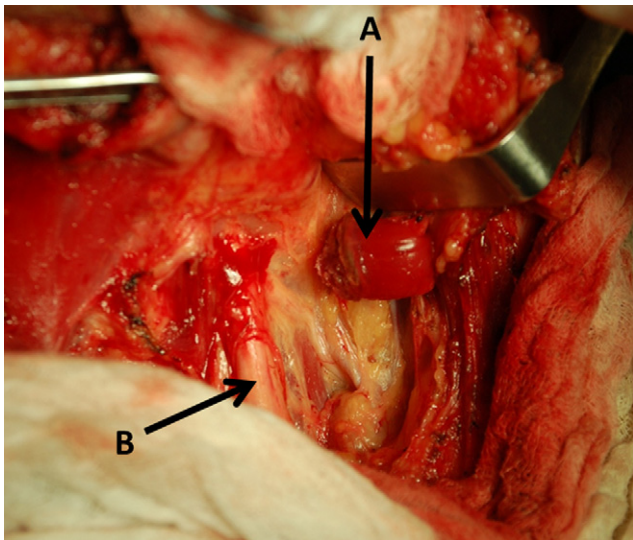
### Node dissection

The first step in the node dissection is the identification of the spinal accessory nerve. The nerve is identified within the posterior triangle, 1 cm posterior and superior to Erb's point, and then traced toward the trapezius muscle within the fascial tissue of level V (Figure 4). Early identification and dissection of the nerve avoids inadvertent injury that may occur when surrounding tissue planes are altered, and avoids mistaking the nerve for one of the cervical rootlets. The spinal accessory nerve is assessed for any tumor involvement, and if not involved, is then skeletonized and preserved. The fascia overlying and investing the trapezius is elevated, and the fascial sheath and underlying node-bearing tissue is removed.<sup>5</sup> This defines the posterior extent of the dissection, and the nodal specimen is next reflected forward from this point. The external jugular nodes present

on the superficial surface of the SCM should be removed and can be left attached to the specimen. It is not necessary to resect the greater auricular nerve, unless grossly involved with disease or if a parotidectomy is performed. Next, an en bloc resection of the suboccipital and retroauricular nodes is performed, and should include the occipital artery and its associated lymphatics (Figure 5). The suboccipital nodes run along the occipital artery, and branches of this artery will need to be divided to remove these nodes.<sup>5</sup> There are nodes deep to the trapezius muscle, superficial to the splenius capitis muscle, that may need to be removed as well. Anatomically, they are enveloped in the fascia that is in continuity with the superficial and deep layers of the deep cervical fascia. The specimen is then reflected inferiorly, and the level VA nodal package is dissected off of the deep neck musculature toward the spinal accessory nerve. Inferiorly, the contents superficial to the omohyoid muscle within the posterior triangle, including the cervical rootlets, are taken with the specimen, as it is reflected anteriorly toward the SCM. The omohyoid muscle is divided to reveal the transverse cervical artery and vein, which are then divided and ligated proximally and distally (Figure 6). With access to the floor of the neck and deep cervical fascia, the brachial plexus is identified, and as the dissection proceeds anteriorly, the superior dissection can be transposed deep to the spinal accessory nerve into the level VB region. The phrenic nerve is preserved, and the SCM is skeletonized to expose the carotid sheath. The anterior aspect of the carotid sheath and the lateral aspect of the strap muscles represent the anterior border of dissection.<sup>3</sup> The muscles of the deep margin include the splenius capitis, levator scapulae, and semispinalis capitis muscles.<sup>5</sup> The fibrofatty tissue is carefully elevated off the fascia enveloping the brachial plexus and the scalene muscles. It is imperative to identify the phrenic nerve and preserve its integrity. The lower cervical rootlets will need to be divided, and as the dissection pro-



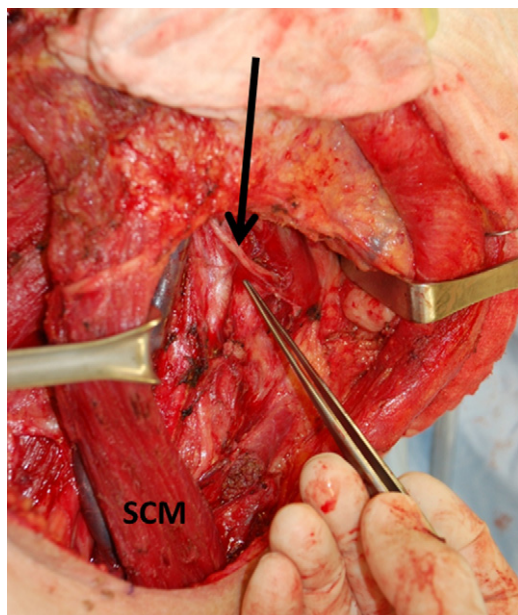
**Figure 5** The arrows collectively point to the en bloc resection of the suboccipital, retroauricular, level V, and external jugular nodes, including the fibrofatty tissue of the posterior triangle. (Color version of figure is available online.)



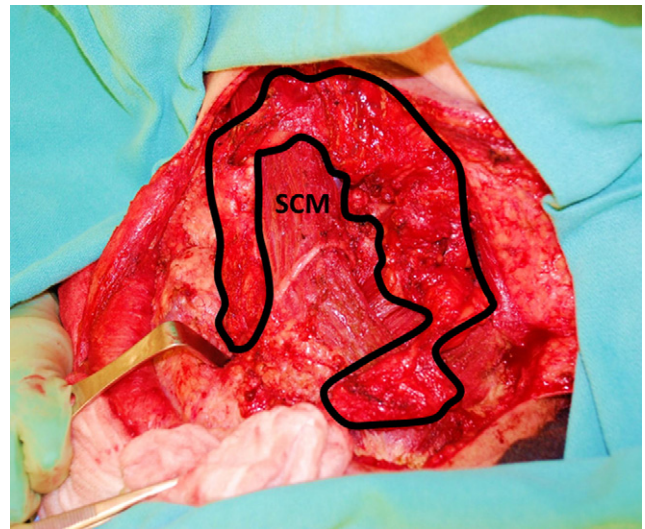
**Figure 6** (A) Division of the omohyoid muscle. (B) Brachial plexus (Color version of figure is available online.)

ceeds superiorly, the rootlets should be divided at a distance from the origin of the phrenic nerve to avoid injury. The posterior aspect of the internal jugular vein is reached, and in the level IV/V junction on the left side (and occasionally on the right), care must be taken to ensure that control of the thoracic duct is achieved. The posterior nodal specimen can then be divided at the posterior aspect of the SCM, or transposed deep to the muscle and maintained attached to the level II-IV specimen.

Attention is then addressed to the anterior dissection, and the inferior border of the parotid gland is released from the SCM. The nodal contents of levels II-IV are then dissected off the deep aspect of the SCM down to the floor of the



**Figure 7** Identification of the hypoglossal nerve observed with retraction of the SCM on the superficial aspect of the internal carotid artery. (Color version of figure is available online.)



**Figure 8** The specimen of lymph node levels II-V plus the retroauricular and suboccipital nodes overlaying their respective neck structures. (Color version of figure is available online.)

neck, along the plane of the cervical rootlets. The inferior facial attachment of the submandibular gland is then divided, exposing the digastric muscle, which is traced posteriorly to the mastoid tip. Deep to the digastric muscle is the hypoglossal nerve, which is traced posteriorly to the internal jugular vein (Figure 7). Once the upper aspect of the vein is dissected off its fascial covering, the spinal accessory nerve can be identified and skeletonized. This maneuver allows elevation of the level IIB nodes, which can then be transposed deep to the nerve in continuity with the main specimen. At that point, the specimen can be elevated broadly off of the floor of the neck, the internal jugular vein, and common carotid artery, as performed in the traditional modified radical neck dissection. The specimen should include nodes of levels II-V plus the retroauricular and suboccipital nodes (Figure 8). The surgeon should assess for a chyle leak due to exposure of the thoracic duct during the deep dissection.

### Drain placement and closure

Two 7-mm round Blake flat suction drains are placed in the depth of the neck, one anterior to the internal jugular vein and one in the posterior triangle, which are secured by 2-0 silk sutures. The neck is closed in multiple layers by closing the platysma with 3-0 Vicryl sutures in an interrupted fashion. Numerous closure techniques for the skin are available to the surgeon, and may include staples, absorbable sutures, and nonabsorbable monofilaments, to name a few. Owing to the large dead space, the surgeon should ensure that the drainage bulbs can hold suction before extubation. Moreover, the potential for a hematoma is highest at extubation, when patients may experience substantial coughing and increased intrathoracic pressures. Therefore, gentle pressure on the neck wound with a towel is recommended during the emergence from anesthesia.

## Complications

Potential complications during the course of a PLND may be vascular, neurological, or cosmetic. A chyle leak through thoracic duct injury or bleeding from venous or arterial sources is likely due to inadequate ligation of vessels. A Valsalva maneuver before closure may identify these potential sources. Neural injuries are most commonly associated with damage to the spinal accessory nerve, greater auricular nerve, or ligated branches of the cervical plexus. Careful attention during the dissection to the depth in the level V region may avoid hemidiaphragmatic elevation from a phrenic nerve injury. Even with careful attention to surgical technique, some patients may require postoperative physical therapy to rehabilitate a neuropraxia to the spinal accessory nerve. Hypoglossal injuries are uncommon, but may occur during careless hemostasis with electrocautery from hypoglossal plexus diathesis.

## Conclusions

The posterolateral neck dissection is an en bloc resection of lymph nodes of levels II-V along with the retroauricular and suboccipital nodes. Our experience at the MD Anderson Cancer Center for >30 years has provided evidence that posterolateral neck dissection for patients with CMM or SCC of the posterior scalp, suboccipital region, retroauricular region, and superior neck region affords a high likeli-

hood of locoregional control, despite the presence of nodal metastasis.

## References

1. Lengelé B, Hamoir M, Scalliet P, et al: Anatomical bases for the radiological delineation of lymph node areas. Major collecting trunks, head and neck. *Radiother Oncol* 85:146-155, 2007
2. Wang Y, Ow TJ, Myers JN: Pathways for cervical metastasis in malignant neoplasms of the head and neck region. *Clin Anat* 25:54-71, 2012
3. Rochlin DB: Posterolateral neck dissection for malignant neoplasms. *Surg Gynecol Obstet* 115:369-373, 1962
4. Goepfert H, Jesse RH, Ballantyne AJ: Posterolateral neck dissection. *Arch Otolaryngol* 106:618-620, 1980
5. Diaz EM Jr, Austin JR, Burke LI, et al: The posterolateral neck dissection. Technique and results. *Arch Otolaryngol Head Neck Surg* 122:477-480, 1996
6. de Langen ZJ, Vermey A: Posterolateral neck dissection. *Head Neck Surg* 10:252-256, 1988
7. Plukker JT, Vermey A, Roodenburg JL, et al: Posterolateral neck dissection: technique and results. *Br J Surg* 80:1127-1129, 1993
8. Goldsmith HS, Shah JP, Kim DH: Malignant melanoma: current concepts of lymph node dissection. *CA Cancer J Clin* 22:216-220, 1972
9. Lin D, Franc BL, Kashani-Sabet M, et al: Lymphatic drainage patterns of head and neck cutaneous melanoma observed on lymphoscintigraphy and sentinel lymph node biopsy. *Head Neck* 28:249-255, 2006
10. Pan WR, Suami H, Taylor GI: Lymphatic drainage of the superficial tissues of the head and neck: anatomical study and clinical implications. *Plast Reconstr Surg* 121:1614-1624, 2008; discussion 1625-1616