

BREAST PATHOLOGY GROSSING GUIDELINES

THINGS TO CONSIDER:

- A. Please review ALL imaging and previous biopsies PRIOR to grossing any breast case.
 - a. It may be helpful to draw out your own guide to assist when grossing
- B. Faxitron your breast to look for clips and calcs. Make sure the clip location(s) correlates with imaging.
 - a. Place mastectomies into Faxitron with **POSTERIOR** surface down
- C. After sectioning your breast into levels, when evaluating the mass size, make sure the dimensions correlate with clinical findings (do not calculate the mass size based off the presence of a mass in certain levels, as this may give you an incorrect and overestimated size).
- D. If you receive a mastectomy with multifocal lesions, measure and document the distance between the lesions in your gross.
- E. **If an axillary tail is present**, determine the reason for this (e.g., axillary lymph node dissection or axillary tail primary tumor site). If the tail is an axillary lymph node dissection, there is no need to ink the axillary tissue. It is helpful to ink the mastectomy prior to removing the axillary tail so that you do not ink the lateral cut surface (which is not a true margin). It is fine if yellow ink extends onto the axillary fat. If the specimen has a suspected/confirmed primary tumor in the axillary tail, the tail should be kept intact and inked with the entire mastectomy. Correlation with the site of tumor(s) is required. Ask for help if needed
- F. Be descriptive in your cassette summary as this is useful when reviewing your slides the following day.
 - a. Document level and location of your sections:
 - i. Level 1- superior OR level 1- upper inner quadrant
 - ii. Level 13- parenchyma between lesion #1 and lesion #2
 - iii. Level 4- lesion #1 at closest approach to posterior margin
 - iv. Level 2- lesion #1 in relation to superior margin

FORMALIN FIXATION

Specimen collection time: The OR nurses record the collection time of all breast specimens in Beaker. This time indicates when the breast specimen has been removed from the patient. The OR staff will contact SurgPath personnel to pick up every breast lumpectomy and mastectomy to try and ensure the ischemic time is within the appropriate limits.

Ischemic time: Breast excisions/re-excisions/lumpectomies/partial mastectomies and all mastectomies (including prophylactic ones) are to be **immediately** (within 1 hour) weighed and placed in 10% neutral buffered formalin (NBF) once received or picked up from the OR. Ideally, this task will be performed by the personnel/technician prior to accessioning the case. The time the specimen was placed in 10% NBF will be written on the specimen container and documented in Case Notes in Beaker. The collection

BREAST PATHOLOGY GROSSING GUIDELINES

time and the time the specimen has been placed in 10% NBF will be used to calculate ischemic time:

(Time tissue placed in formalin) – (Collection time) = Ischemic Time

Due to CAP-recommended guidelines for ER, PR, and HER2/neu (including FISH) testing, as much as possible, specimens should be placed in formalin within one hour after surgery. Furthermore, the breast tissue should be in contact with formalin for 6-48 hours, not to exceed 72 hours. Therefore, when a specimen comes in late on Friday, gross the specimen such that you identify the tumor and submit sections of the tumor for the Friday late processor. If the specimen is still very fresh, then please submit the remaining sections (including lymph nodes) during the weekend such that they'll run on the Sunday processor.

When a specimen comes in on the weekend (occasionally on Saturdays), then please gross the entire specimen and submit sections for the Sunday processor. For such Saturday specimens, waiting until Monday to submit sections for the Monday processor will result in suboptimal testing conditions for breast biomarkers, since this will exceed the recommended 48-hour ideal formalin fixation time frame.

As always, RECORD THE ISCHEMIC TIME **AND** THE FORMALIN FIXATION TIME

Note: The exception to this is when the requisition states 'Rule out Lymphoma' or a prior core needle biopsy diagnosis was reported as lymphoma. In these cases, call for a lymphoma work-up and DO NOT fix the breast tissue in 10% NBF.

Calculating formalin fixation times

Monday – Friday

calculate fixation time until 12am

Saturday - Sunday

calculate fixation time until 8pm on Sunday

Holiday weekends

contact histology to ensure cassettes are transferred from formalin and placed into alcohol so as not to exceed the formalin fixation time (6-72 hours). The tissue is in formalin for 2 hours on the processor, so please be mindful of accounting for this when calculating fixation times!

Calculating formalin fixation times of **Breast Biopsies:**

Routine breast core (bx placed in formalin before 2pm) → calculate fixation time until 9pm

Late breast core (bx placed in formalin after 2 pm) → calculate time to 11pm

BREAST PATHOLOGY GROSSING GUIDELINES

SURGICAL PATHOLOGY SPECIMEN RADIOGRAPHY: FAXITRON

Faxitron image(s) must be obtained and uploaded into Beaker for the following specimen types:

- 1) All excisional biopsy/lumpectomy/partial mastectomy specimens in order to verify microclip(s) and/or microcalcifications
- 2) All mastectomy specimens
- 3) Consider Faxitron imaging paraffin blocks of needle core biopsies as needed for microcalcifications (when initial 3 H&E sections do not show calcs and specimen radiography showed calcs)

When an image is taken, an annotation of the patient's name and surgical case number must be included in each image. Any additional annotations that are relevant to the particular case should also be included, for instance, measurement(s) and relationships of specific anatomic locations to lesion(s), size of tumor, area of calcifications, location of suspicious area(s), summary of sections, etc.

Image(s) should be uploaded into the case in Beaker; this must be noted in the gross description for billing purposes. (i.e., "A Faxitron image was taken of the specimen.")

BREAST PATHOLOGY GROSSING GUIDELINES

Specimen Type: MASTECTOMY

Procedure:

1. Review patient's pertinent history and imaging in EPIC in order to correlate with gross findings
2. Weigh (fresh weight should be written on specimen container)
3. Orient specimen (typically- long-lateral; short-superior)
 - a. Quadrants will be determined based on location of nipple
4. Measure (entire specimen, skin ellipse, nipple, and axillary tail if present)
 - a. Provide oriented dimensions of breast (ANT-POST; MED-LAT; SUP-INF)
 - i. Medial-lateral dimension DOES NOT include axillary tail
 - ii. Measure axillary tail separately
5. Check skin for scar, puckering or ulcerations
6. Document if nipple is everted, inverted, or retracted
7. Faxitron (prior to inking) and look for microclip(s) and calcifications
 - a. Include "A Faxitron image is taken to reveal..." in your gross
 - b. Place breast with POSTERIOR surface down in the Faxitron
8. Ink specimen:

Blue- superior	Purple-medial
Green- inferior	Yellow- lateral
Orange- anterior/superficial	Black- posterior/deep

****If nipple sparing-** ink sub-areolar disc (use color which hasn't been used for medial)

****If axillary tail present-**no need to ink axillary tail tissue. It is helpful to ink mastectomy prior to removing the axillary tail so that you do not ink the lateral cut surface (which is not a true margin). It is fine if yellow ink extends onto the axillary fat. Please ask for help if needed.

9. If lesion is NOT close to nipple (where a perpendicular section would best demonstrate skin involvement), amputate the nipple. Take a shave of the nipple base and further serially section the amputated nipple.
 - a. This maximizes the surface area of epidermis evaluated microscopically to check for Paget's and/or other lesions
10. Serially section, from medial to lateral into complete 1cm or thinner cross sections
 - a. Document number of levels
 - b. Document in which level the nipple is located
11. Measure lesion(s)
 - a. Indicate location (quadrant and clock face orientation)
 - b. Give distance to all margins, nipple
 - c. If multiple lesions present give the distance between the lesions/biopsy sites and distance between the farthest ends of the lesion (in case the grossly separate lesions are one large lesion)

BREAST PATHOLOGY GROSSING GUIDELINES

12. Palpate and section through axillary tail for lymph nodes (try to find 10-20 LN at minimum) –Only if axillary tail is removed for lymph node dissection and not for primary tumor evaluation
- If oriented (typically one suture- level 1; two sutures-level 2) cut into two levels and indicate which LN are in each level in cassette summary
 - Document if there are any biopsy clips present and indicate corresponding LN in cassette summary
 - Even if no axillary tail is present try and palpate the upper outer quadrant for lymph nodes

Suggested sections for histology:

<p>- Prophylactic</p>	<ul style="list-style-type: none"> ▪ Nipple: <ul style="list-style-type: none"> * If lesion is subareolar, DO NOT shave off nipple. This relationship is important in staging. - Serial sections of amputated nipple in one cassette - Shave of base of nipple in one cassette ▪ Nipple sparing: ink and section the breast from medial→ lateral and submit 1 cassette (1-2 perpendicular sections). Perpendicular sectioning is important for determining margin distance on incidental lesions! ▪ Additional 2 cassettes per quadrant, focusing on fibrous tissue and/or calcs
<p>- BRCA or CHEK2 mutations (when there are NO gross lesions or biopsy sites)</p>	<ul style="list-style-type: none"> ▪ Nipple: <ul style="list-style-type: none"> * If there is a lesion located subareolar, DO NOT shave off nipple. This relationship is important in staging. Section from medial→lateral and then submit perpendicular section of mass in relation to nipple - Serial sections of amputated nipple in one cassette - Shave of base of nipple in one cassette ▪ Nipple sparing: ink and section the breast from medial→ lateral and submit 1 cassette (1-2 perpendicular sections). Perpendicular sectioning is important for determining margin distance on incidental lesions! ▪ All lymph nodes ▪ Additional 2 cassettes per quadrant, focusing on fibrous tissue and/or calcs

BREAST PATHOLOGY GROSSING GUIDELINES

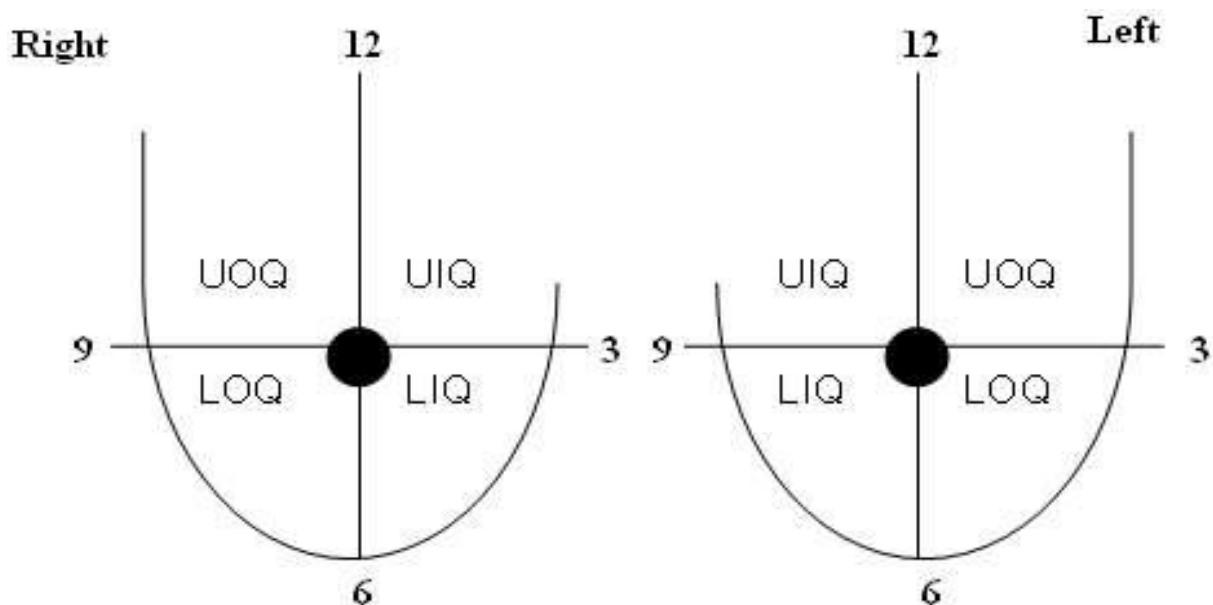
<p>- DCIS/ADH/LCIS</p>	<ul style="list-style-type: none"> ▪ Nipple: <ul style="list-style-type: none"> * If lesion is subareolar, DO NOT shave off nipple. This relationship is important in staging. Section from medial→lateral and then submit perpendicular section of mass in relation to nipple - Serial sections of amputated nipple in one cassette - Shave of base of nipple in one cassette ▪ Nipple sparing: ink and section the breast from medial→ lateral and submit 1 cassette (1-2 perpendicular sections). Perpendicular sectioning is important for determining margin distance on incidental lesions! ▪ Sample biopsy site(s)—you often may not grossly see a lesion! <ul style="list-style-type: none"> - DCIS often looks more pink than surrounding fibrous tissue. It is important to document the extent of DCIS, so sample these areas, if grossly suspicious. - Include close margins - Sample tissue between biopsy sites, if applicable ▪ <u>Two flank levels</u> before and & after the biopsy site(s) ▪ All lymph nodes ▪ Additional 1 cassette per quadrant, focusing on fibrous tissue and/or calcs
<p>- IDC - IDC with DCIS - ILC</p>	<ul style="list-style-type: none"> ▪ Nipple: <ul style="list-style-type: none"> * If lesion is subareolar, DO NOT shave off nipple. This relationship is important in staging. Section from medial→lateral and then submit perpendicular section of mass in relation to nipple - Serial sections of amputated nipple in one cassette - Shave of base of nipple in one cassette ▪ Nipple sparing: ink and section the breast from medial→ lateral and submit 1 cassette (1-2 perpendicular sections). Perpendicular sectioning is important for determining margin distance on incidental lesions! ▪ 4-6 sections of lesion <ul style="list-style-type: none"> - Include close margins, if possible - Include area of biopsy site/clip - Sample tissue between lesions, if applicable - Relationship to skin overlying lesion to include scar, if possible ▪ <u>One flank level</u> before and & after the lesion <ul style="list-style-type: none"> - DCIS often looks more pink than surrounding fibrous tissue. It is important to document the extent of DCIS, so sample these areas thoroughly around the lesion, if grossly suspicious. ▪ Additional 1 cassette per quadrant, focusing on fibrous tissue and/or calcs

BREAST PATHOLOGY GROSSING GUIDELINES

<p>- Multicentric Lesions</p>	<ul style="list-style-type: none"> ▪ Nipple: <ul style="list-style-type: none"> * If lesion is subareolar, DO NOT shave off nipple. This relationship is important in staging. Section from medial→lateral and then submit perpendicular section of mass in relation to nipple - Serial sections of amputated nipple in one cassette - Shave of base of nipple in one cassette ▪ Nipple sparing: ink and section the breast from medial→ lateral and submit 1 cassette (1-2 perpendicular sections). Perpendicular sectioning is important for determining margin distance on incidental lesions! ▪ Sections of every level of lesion <ul style="list-style-type: none"> - Include close margins - Include area of biopsy site/clip - Sample tissue between lesions - Relationship to skin overlying lesion to include scar, if possible ▪ <u>One flank level</u> before and & after each lesion ▪ All lymph nodes ▪ Additional 1 cassette per quadrant, focusing on fibrous tissue and/or calcs
<p>- Post neo-adjuvant chemotherapy (NACT)</p>	<ul style="list-style-type: none"> ▪ Nipple: <ul style="list-style-type: none"> * If lesion is subareolar, DO NOT shave off nipple. This relationship is important in staging. Section from medial→lateral and then submit perpendicular section of mass in relation to nipple ▪ Serial sections of amputated nipple in one cassette ▪ Shave of base of nipple in one cassette ▪ Nipple sparing: ink and section the breast from medial→ lateral and submit 1 cassette (1-2 perpendicular sections). Perpendicular sectioning is important for determining margin distance on incidental lesions! ▪ Entirely embed the tumor site if tumor bed can fit in 15 cassettes or fewer OR if too large, submit 2 sections per 1 cm of the tumor bed <ul style="list-style-type: none"> - Include close margins - Include area of biopsy site/clip, if applicable - Relationship to skin overlying lesion to include scar, if possible ▪ All lymph nodes ▪ <u>One flank level</u> before and & after the tumor bed ▪ Additional 1 cassette per quadrant, focusing on fibrous tissue and/or calcs
<p>- Prior lumpectomy cavity</p>	<ul style="list-style-type: none"> ▪ Nipple:

BREAST PATHOLOGY GROSSING GUIDELINES

	<p>* If lesion is subareolar, DO NOT shave off nipple. This relationship is important in staging. Section from medial→lateral and then submit perpendicular section of mass in relation to nipple</p> <ul style="list-style-type: none"> ▪ Serial sections of amputated nipple in one cassette ▪ Shave of base of nipple in one cassette ▪ Nipple sparing: ink and section the breast from medial→ lateral and submit 1 cassette (1-2 perpendicular sections). Perpendicular sectioning is important for determining margin distance on incidental lesions! ▪ 2 cassettes per the largest dimension of the cavity (e.g. 10 cassettes if cavity is 5 cm) <ul style="list-style-type: none"> - Include close margins ▪ Check prior path to see if there were close or positive margins from prior excision/lumpectomy so that you can properly inspect and sample those areas <ul style="list-style-type: none"> - Include area of biopsy site/clip, if applicable - Relationship to skin overlying lesion to include scar, if possible ▪ All lymph nodes ▪ Additional 1 cassette per quadrant, focusing on fibrous tissue and/or calcs
--	--



BREAST PATHOLOGY GROSSING GUIDELINES

Gross Template:

MMODAL COMMAND: "INSERT SKIN SPARING MASTECTOMY"

It consists of a [*weight in grams****] g, oriented mastectomy specimen with sutures indicating [*describe orientation/short -superior****]. The specimen measures [***] cm (medial - lateral) x [***] cm (superior-inferior) x [***] cm (anterior - posterior). There [*is/is no***] axillary tail present. A Faxitron image is taken to reveal [*comment on calcifications and presence/absence of biopsy clip(s)****].

The specimen is serially sectioned from medial to lateral into [***] levels. The retro areolar area is located in level [***]. Sectioning reveals a [*describe lesion/ill-defined area of fibrous tissue in three dimensions****]. The [*lesion/fibrous area*] is located in levels [***]. A [*indicate shape of clip****] clip is identified in level [indicate level and if inside/outside of mass***]. The lesion measures [***] cm from anterior, [***] cm from posterior, [***] cm from medial, [***] cm from lateral, [***] cm from superior, [***] cm from inferior, and [***] cm from the [*retro areolar/nipple****].

The remainder of the uninvolved parenchyma consists of [*give percentage****] white-tan fibrous tissue and [*give percentage****] yellow-tan adipose tissue. The lateral aspect is palpated and [*number of lymph nodes/no****] lymph nodes are identified.

[*All identified lymph nodes are submitted in their entirety and representative sections of the remaining specimen are submitted/ The lesion is entirely submitted and representative sections of the remaining specimen are submitted/ Representative sections are submitted****].

Total Ischemic Time: [*time in formalin minus collection time****] minutes

Total Formalin fixation Time: [*collection time to 12 am Monday-Friday****] hours

INK KEY:

Blue	Superior
Green	Inferior
Purple	Medial
Yellow	Lateral
Orange	Anterior
Black	Deep
Red	Subareolar

[*insert cassette summary****]

MMODAL COMMAND: "INSERT MASTECTOMY"

It consists of a [*weight in grams****] g, oriented mastectomy specimen with sutures indicating [*describe orientation/short -superior****]. The specimen measures [***] cm (medial - lateral) x [***] cm (superior-inferior) x [***] cm (anterior - posterior). There [*is a/is no****] skin ellipse present on the anterior surface. The skin ellipse measures [*give measurement in two dimensions****] cm. The [*everted/inverted/flattened****] nipple measures [*give measurement in three dimensions****] cm. There [*is/is no***] axillary tail present. A Faxitron image is taken to reveal [*comment on calcifications and presence/absence of biopsy clip(s)****].

The specimen is serially sectioned from medial to lateral into [***] levels. The nipple is located in level [***]. Sectioning reveals a [*describe lesion/ill-defined area of fibrous tissue in three dimensions****]. The [*lesion/fibrous area*] is located in levels [***]. A [*indicate shape of clip****] clip is identified in level [indicate level and if inside/outside of mass***]. The lesion measures [***] cm from anterior/skin surface, [***] cm from posterior, [***] cm from medial, [***] cm from lateral, [***] cm from superior, [***] cm from inferior, and [***] cm from the nipple.

BREAST PATHOLOGY GROSSING GUIDELINES

The remainder of the uninvolved parenchyma consists of [*give percentage****] white-tan fibrous tissue and [*give percentage****] yellow-tan adipose tissue. The lateral aspect is palpated and [*number of lymph nodes/no****] lymph nodes are identified.

[*All identified lymph nodes are submitted in their entirety and representative sections of the remaining specimen are submitted/ The lesion is entirely submitted and representative sections of the remaining specimen are submitted/ Representative sections are submitted****].

Total Ischemic Time: [*time in formalin minus collection time****] minutes

Total Formalin fixation Time: [*collection time to 12 am Monday-Friday****] hours

INK KEY:

Blue	Superior
Green	Inferior
Purple	Medial
Yellow	Lateral
Orange	Anterior
Black	Deep

[*insert cassette summary****]

Sample Cassette Submission: Generally, you should submit around **10-20 cassettes**.

Case with biopsy proven invasive carcinoma

A1: Nipple, serially sectioned

A2: Nipple base, shave

A3: Mass in relation to closest margin (anterior)

A4-A6: Full cross section of mass in greatest dimension to include biopsy site (A5), trisected and submitted from superior to inferior

A7: Unremarkable parenchyma medial to mass

A8: Unremarkable parenchyma lateral to mass

A9: Upper outer quadrant- unremarkable parenchyma, level 2

A10: Upper inner quadrant- unremarkable parenchyma, level 5

A11: Lower outer quadrant- unremarkable parenchyma, level 11

A12: Lower inner quadrant- unremarkable parenchyma, level 14